

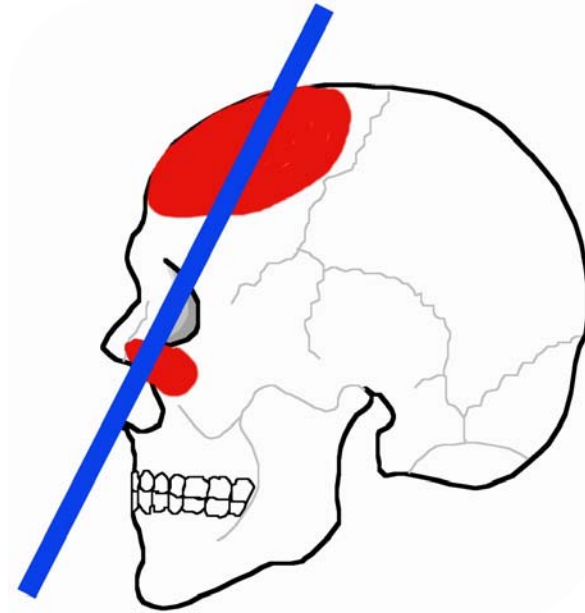
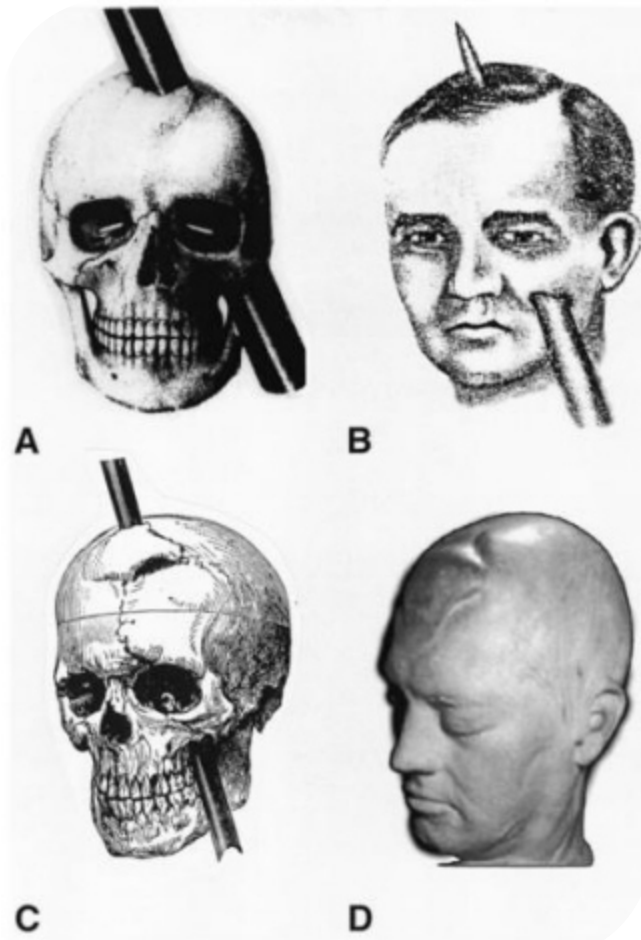
# Neural Basis of Decision Making

Mary ET Boyle, Ph.D.

Department of Cognitive Science  
UCSD



# Recall: Phineas Gage:



- Sept. 13, 1848
- Working on the rail road
- Rod impaled his head.
- 3.5' x 1.25"
- 13 pounds

Austin, was found drowned near the south bridge in Salem; it is supposed he fell overboard between 2 and 3 o'clock in the morning, while fishing.

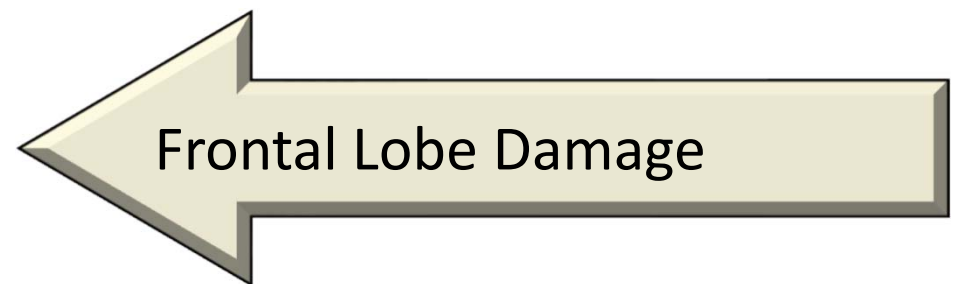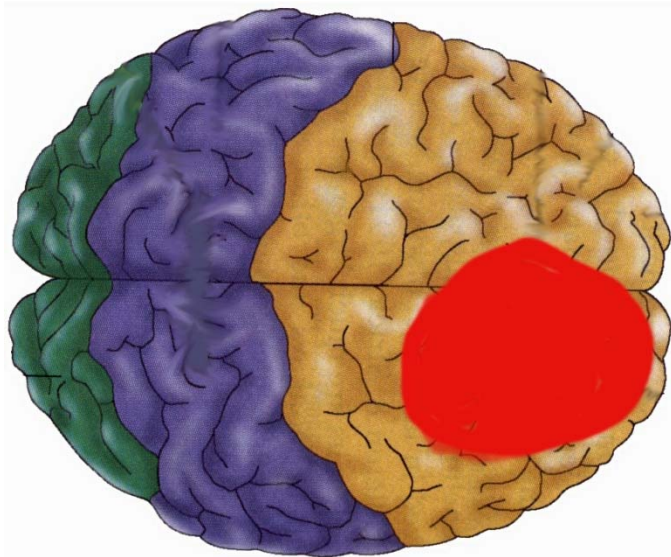
*Horrible Accident.*—As Phineas P. Gage, a foreman on the railroad in Cavendish, was yesterday engaged in tamping for a blast, the powder exploded, carrying an iron instrument through his head an inch and a fourth in circumference, and three feet and eight inches in length, which he was using at the time. —The iron entered on the side of his face, shattering the upper jaw, and passing back of the left eye, and out at the top of the head.

The most singular circumstance connected with this melancholy affair is, that he was alive at two o'clock this afternoon, and in full possession of his reason, and free from pain — *Ludlow, Vt., Union.*

The chief of the Philadelphia dogkillers, a black man named George Horsey, attempted to kill his wife. He broke into her room armed with a pistol and knife; she threw herself out of the second story window to escape, breaking her leg in the fall; he pursued her, and attacked and injured her severely. She was taken to the hospital. Horsey was fully committed for trial.

# What happened to Phineas?

- He survived!!
- Major personality change
- “His mind was radically changed ...
- No longer the same person.”
- Fitful, irreverent, grossly profane, impatient, obstinate...




# PREFRONTAL LOBOTOMY IN THE TREATMENT OF MENTAL DISORDERS\*


*By* WALTER FREEMAN, M.D., Ph.D., F.A.C.P.  
*and*  
JAMES W. WATTS, M.D.  
Washington, D. C.

Southern Medical Journal, January 1937





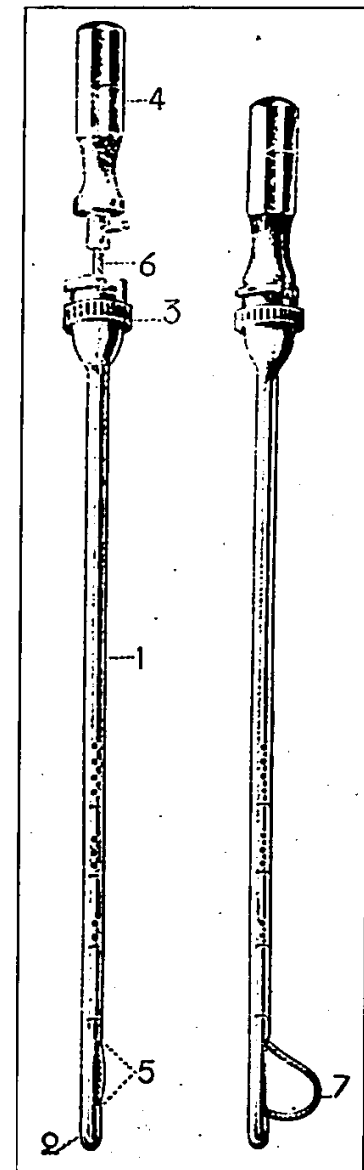
This procedure has been followed by us in six cases during the past two months, and we are able to report in very tentative fashion our results to date. We are able to say, with Moniz, that no patient has died and none has been made worse. All of our patients except one have returned home, and some of them are no longer in need of nursing care. All of them are more comfortable, having been relieved of certain symptoms that previously had been very troublesome. It is as if the "sting" of the psychosis had been drawn. It is much too soon to say that they have been permanently relieved of their symptoms, and we do not wish even to mention the



word cure. Furthermore, these patients have not been subjected as yet to any of the finer psychological tests for delayed response, imagination, and constructive ability, tests that might elicit finer degrees of deficit due to the lesions produced in the frontal lobes. One of our patients has returned to her former job.



Prefrontal lobotomy has been performed in our cases as a means for relief of symptoms in patients who were more or less disabled as a result of certain mental states that had proven refractory to conservative methods of handling. In all of our patients there was a substratum, a common denominator of worry, apprehension, anxiety, insomnia and nervous tension, and in all of them these particular symptoms have been relieved to a greater or lesser extent. In some patients there has been amelioration or even disappearance of certain other symptoms such as disorientation, confusion, phobias, hallucinations, and delusions that were present before operation. The physical condition of our patients has also improved, and the visceral symptoms have tended to subside. Certain neurological symptoms such as perseveration of speech, increase of reflexes, and disturbance of vesical control which developed immediately following operation in several patients, disappeared within a few days, and we have observed no pupillary disturbances, no ataxia and no paralysis.





*Case 1.*—The chief complaints of Mrs. A. H., aged 63,\* were nervousness, insomnia, depression of spirits, anxiety and insecurity, getting progressively worse for a year. She had always been high-strung, emotional, and easily fatigued, a meticulous housekeeper with several previous nervous breakdowns. For ten years she had taken sedatives in order to sleep. She was unable to adjust herself to the idea of growing old, became progressively more agitated, tense and emotional; for instance, when she was asked about colds or sore throat she became agitated, saying, "Why do you want to know? Why do you ask me that? What does that mean? What has that got to do with it?" During the examination she was wringing her hands, moving about in bed, and trying to get out.

Prefrontal lobotomy was carried out on September 14, 1936, using the technic described by Moniz. In making the third anterolateral section on the right side some bleeding was encountered and a small vessel was found adherent to the leucotome when withdrawn.

Four hours later she greeted the physician in a calm voice, holding out her hand and declaring that she felt much better. The next day the following conversation was carried out:

D.: "Do you have any of your old fears?"

P.: "No."

D.: "What were you afraid of?"

P.: "I don't know. I seem to forget."

D.: "Do you remember being upset when you came here?"

P.: "Yes, I was quite upset, wasn't I?"

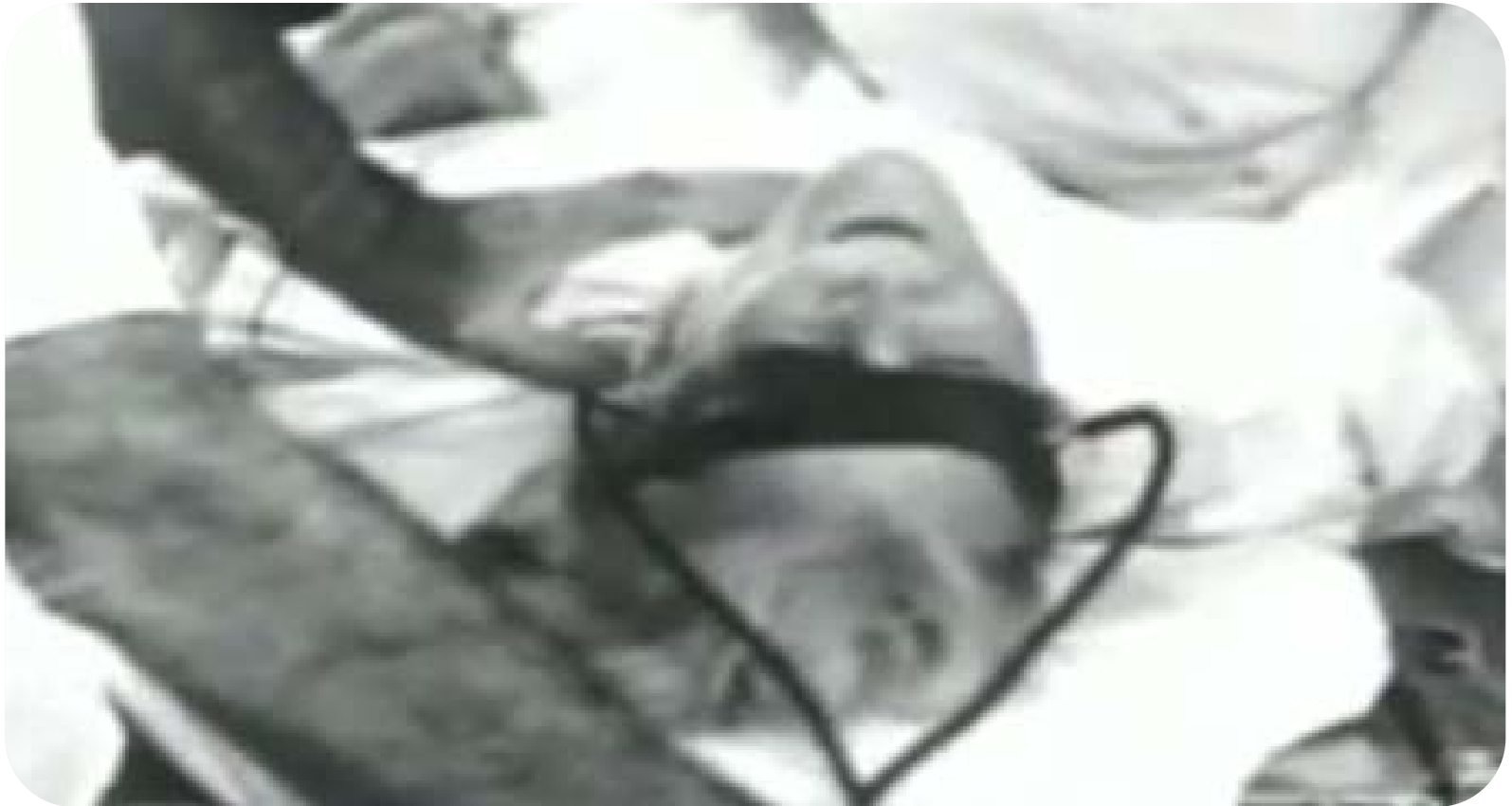D.: "What was it all about?"

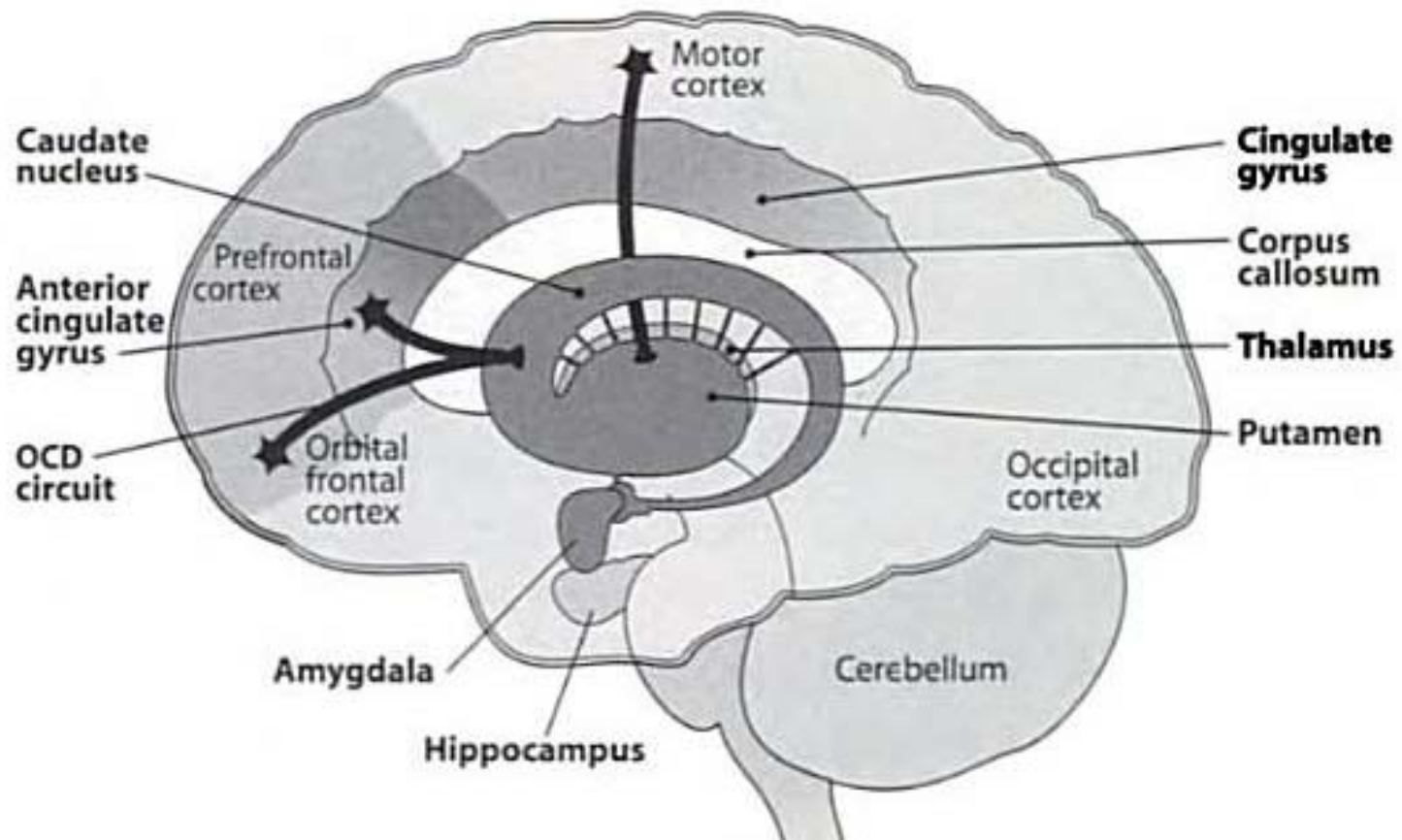
P.: "I don't know. I seem to have forgotten. It doesn't seem important now."

The patient had a setback on September 20, when she became restless, confused, showed perseveration in speech, and finally aphasia, and showed some rubbing and rolling movements. Her expression was serene, however, and this phase passed off fairly rapidly.

She was discharged from the hospital about eighteen days after operation.

When seen recently she stated that her anxiety and apprehension were no longer present, that she could sit down and plan out a course of procedure better than she could before because of freedom from distraction; that she was content to grow old gracefully and that she could enjoy external events more than she could before because she was not always impelled to be on the go herself. She managed the apartment and kept the household accounts as well as she ever did; enjoyed rides in the automobile and the company of friends who formerly used to exhaust her. She slept well at night, although occasionally requiring a little sedative. She noticed some loss of spontaneity which she described as being subdued. Her husband said that she was more normal than she had ever been.





**Figure 1:** This side view of the brain shows some of its key structures, including those involved in OCD. In the "OCD circuit," neurons that project from the orbital frontal cortex and the anterior cingulate gyrus to the caudate nucleus are overactive, generating the persistent sense that something is amiss.





Available online at [www.sciencedirect.com](http://www.sciencedirect.com)

SCIENCE @ DIRECT®

Brain and Cognition 55 (2004) 11–29

---

Brain  
and  
Cognition

---

[www.elsevier.com/locate/b&c](http://www.elsevier.com/locate/b&c)

# The functions of the orbitofrontal cortex

Edmund T. Rolls\*

*Department of Experimental Psychology, University of Oxford, South Parks Road, Oxford OX1 3UD, England, UK*

Accepted 14 March 2003

Available online 2 April 2004

Macaques with lesions of the orbitofrontal cortex are impaired at tasks which involve learning about which stimuli are rewarding and which are not, and especially in altering behaviour when reinforcement contingencies change. The monkeys may respond when responses are inappropriate, e.g., no longer rewarded, or may respond to a non-rewarded stimulus.



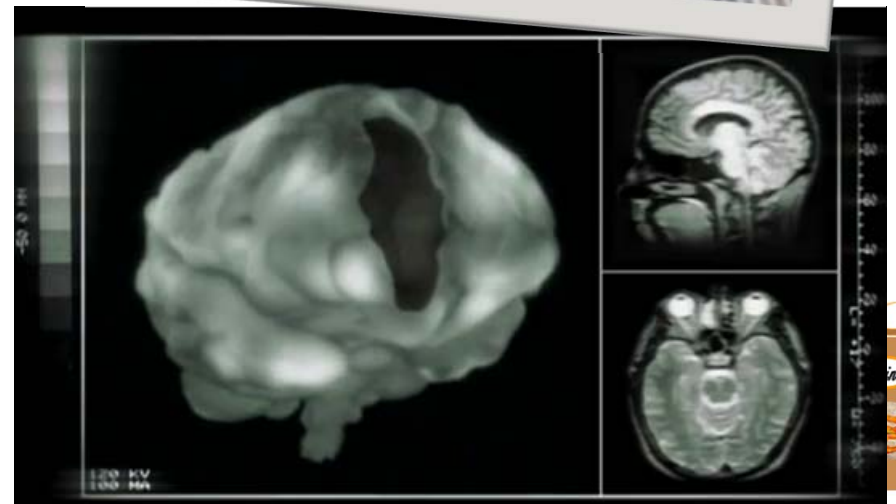
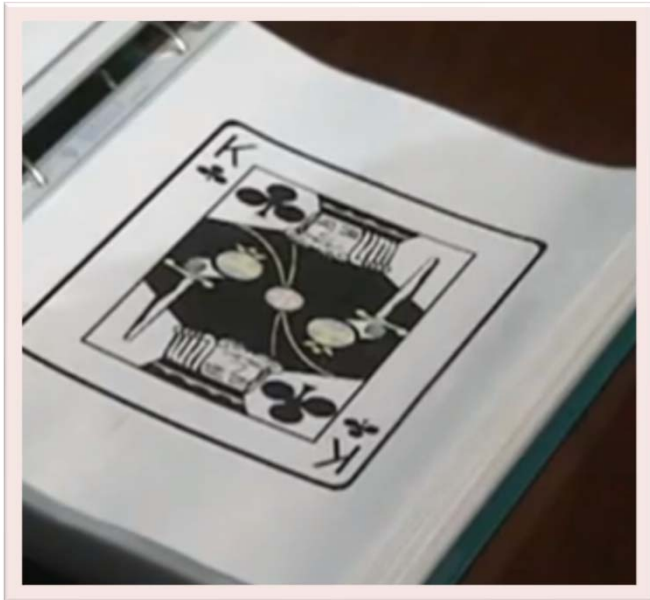
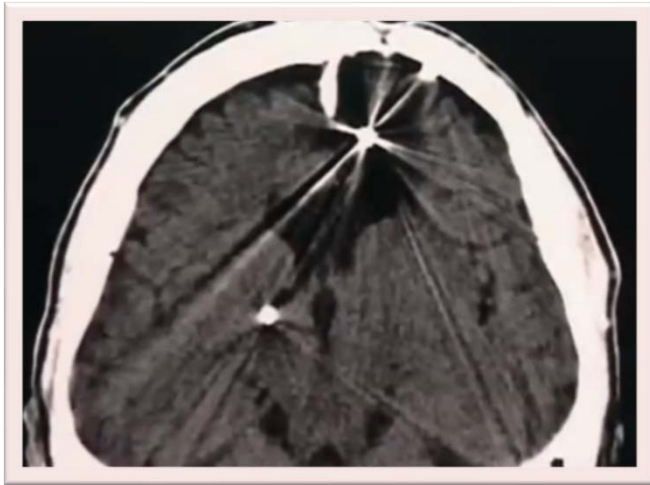




<https://youtu.be/5B2pQkqM6nc?t=87>



# The modern day Phineas Gage



# Iowa Card Gambling Test

- Participants are presented with 4 decks of cards.
- Each time they choose a card they will win money → reward.
- Goal: maximize \$\$\$

Every card drawn will earn money.

Occasional cards will have a penalty.

- Sometimes particular cards in a deck will cause them to lose some money.
- Decks differ from each other in terms of rewards and losses.

- Some decks are “good” decks → over the long time the player will win more money.
- Some decks are “bad” decks → long term player will lose.

Over time, subjects sample cards from all 4 decks

## Normal

sample from each deck

good at detecting “good” decks

Galvanic skin response – stress response over “bad” decks

## OFC dysfunction patients

perseverate with bad decks

they “know” that they are losing money

never develop the physiological reaction to impending punishment.



---

OPINION

# The neural basis of human moral cognition

---

*Jorge Moll, Roland Zahn, Ricardo de Oliveira-Souza, Frank Krueger  
and Jordan Grafman*

NATURE REVIEWS | NEUROSCIENCE VOLUME 6 | OCTOBER 2005 | **799**



## Defining morality

‘Moral’ (derived from the Latin *moralis*)  
and ‘ethical’ (from the Greek *êthikos*)  
*originally* referred to the consensus of  
manners and customs within a social  
group, or to an inclination to behave in  
some ways but not in others.



How does the human moral mind emerge from the interaction of biological and cultural factors?

How can the context-dependent nature of moral cognition be explained by neuroscience?

How does moral cognition relate to emotion and motivation, and what are their neural substrates?



# The neural basis of moral cognition

- *Moral behavior impairment*

Impairment in 'moral sense' , or 'moral insanity' , was first formally described as a *“perversion of natural feelings, affections, inclinations, temper, habits, moral dispositions, and natural impulses”*



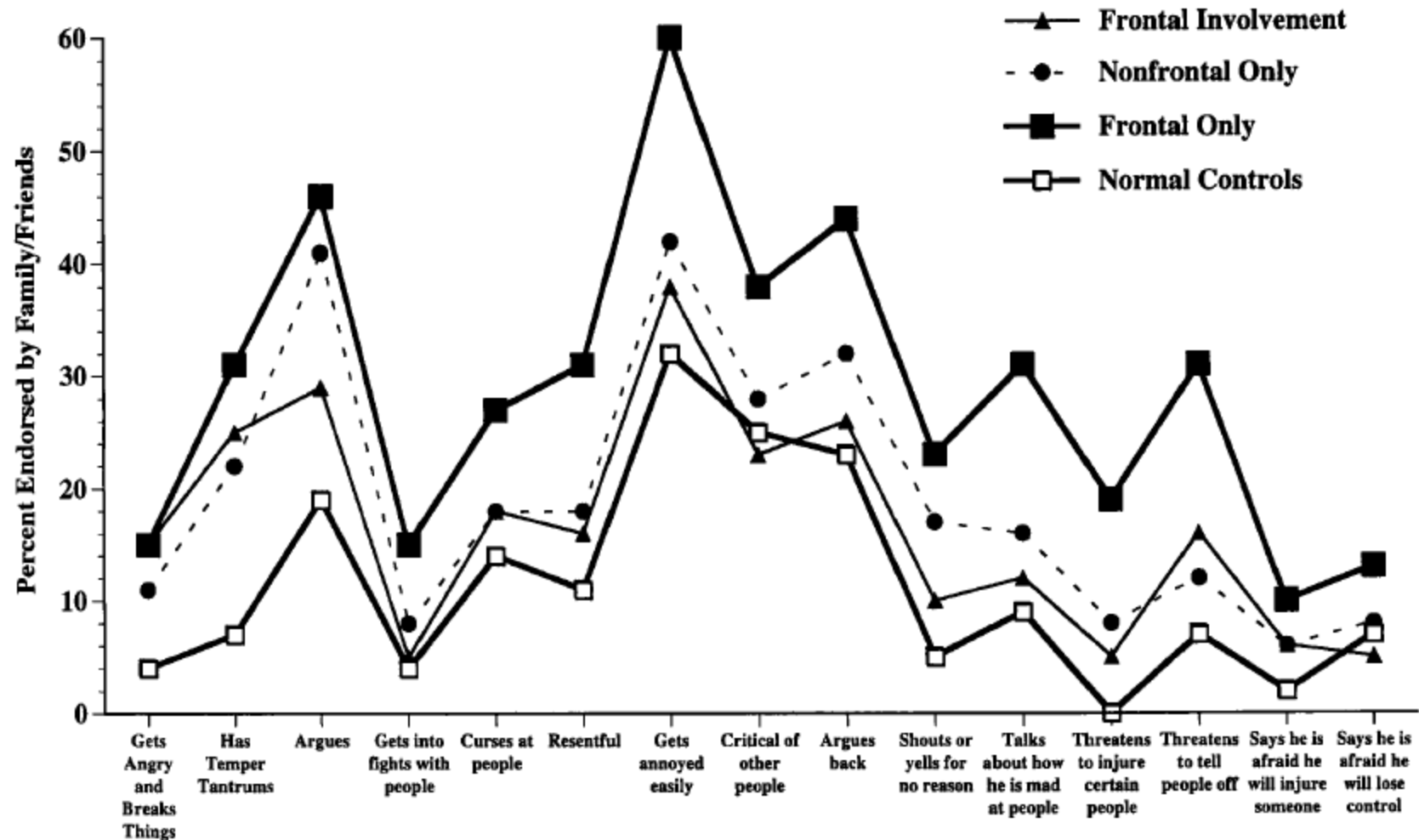


# Frontal lobe injuries, violence, and aggression:

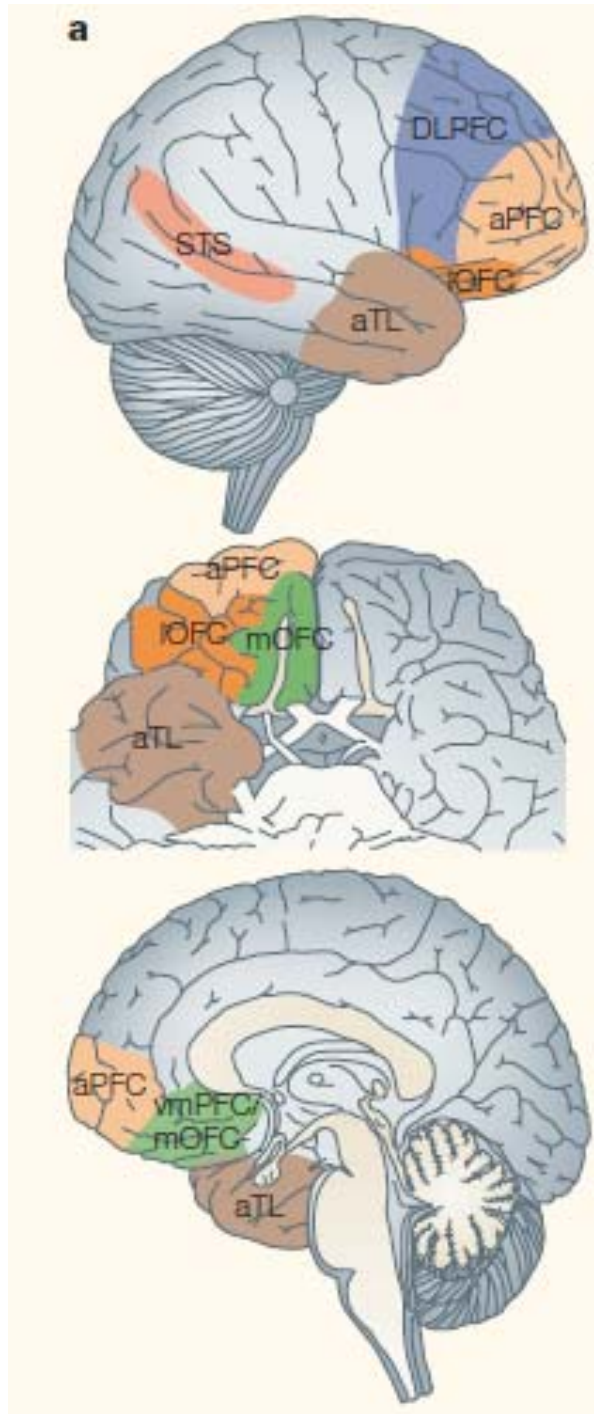
## A report of the Vietnam Head Injury Study

J. Grafman, PhD; K. Schwab, PhD; D. Warden, MD; A. Pridgen, BS; H.R. Brown, HMCM, USN (Ret); and  
A.M. Salazar, MD

**Article abstract**—Knowledge stored in the human prefrontal cortex may exert control over more primitive behavioral reactions to environmental provocation. Therefore, following frontal lobe lesions, patients are more likely to use physical intimidation or verbal threats in potential or actual confrontational situations. To test this hypothesis, we examined the relationship between frontal lobe lesions and the presence of aggressive and violent behavior. Fifty-seven normal controls and 279 veterans, matched for age, education, and time in Vietnam, who had suffered penetrating head injuries during their service in Vietnam, were studied. Family observations and self-reports were collected using scales and questionnaires that assessed a range of aggressive and violent attitudes and behavior. Two Aggression/Violence Scale scores, based on observer ratings, were constructed. The results indicated that patients with frontal ventromedial lesions consistently demonstrated Aggression/Violence Scale scores significantly higher than controls and patients with lesions in other brain areas. Higher Aggression/Violence Scale scores were generally associated with verbal confrontations rather than physical assaults, which were less frequently reported. The presence of aggressive and violent behaviors was not associated with the total size of the lesion nor whether the patient had seizures, but was associated with a disruption of family activities. These findings support the hypothesis that ventromedial frontal lobe lesions increase the risk of aggressive and violent behavior.



Percentage of items on aggression and violence from the Katz Adjustment Scale (an inventory that indicates the behavioral adjustment of the subject to home life) endorsed by friends and family members of controls and patients whose lesions included or were restricted to the frontal lobes or to nonfrontal regions.



## Brain regions crucial for moral cognition:

### Cortical regions include:

- the anterior prefrontal cortex (aPFC),
- the medial and lateral orbitofrontal cortex (mOFC and IOFC),
- the dorsolateral PFC (DLPFC; mostly the right hemisphere)
- additional ventromedial sectors of the PFC (vmPFC),
- the anterior temporal lobes (aTL)
- the superior temporal sulcus (STS)

## Brain regions crucial for moral cognition:

Subcortical regions include:

amygdala,

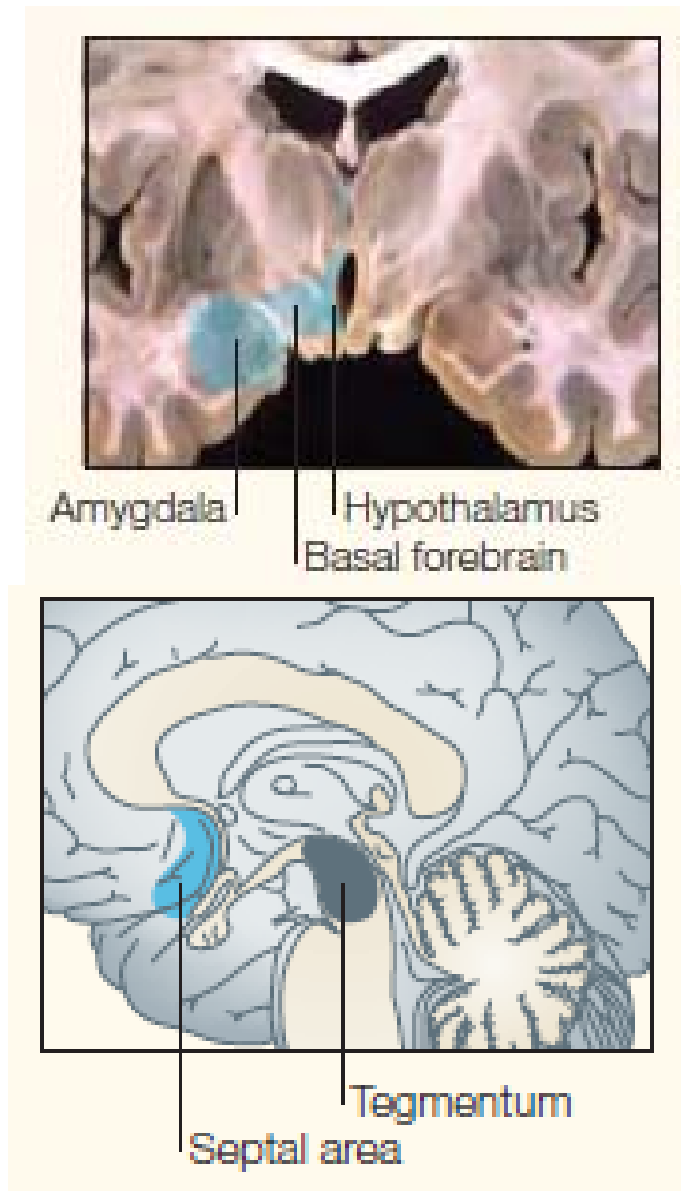
ventromedial hypothalamus,

septal area and nuclei

Basal forebrain (especially ventral striatum/pallidum)

The walls of the third ventricle

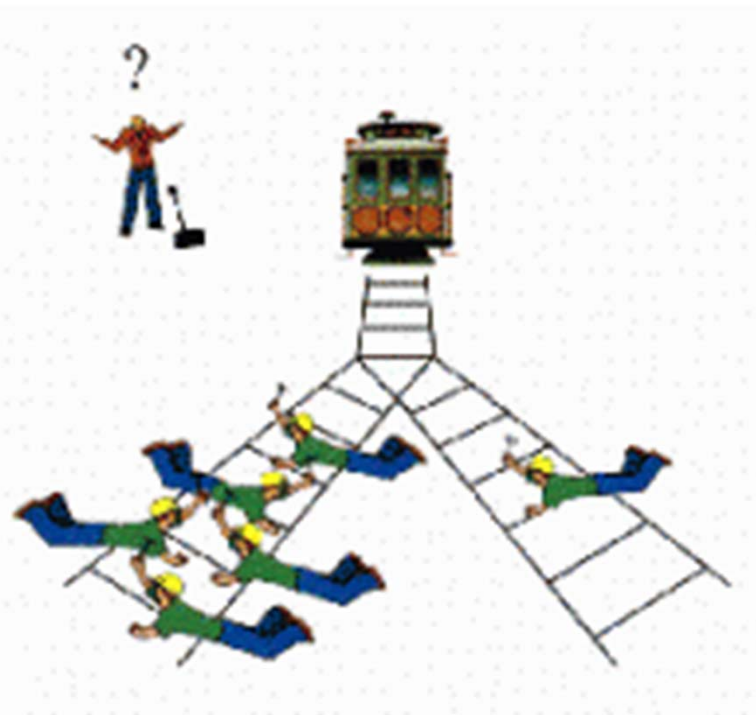
Rostral brainstem tegmentum



In resolving moral dilemmas,  
should emotion  
be our guide?




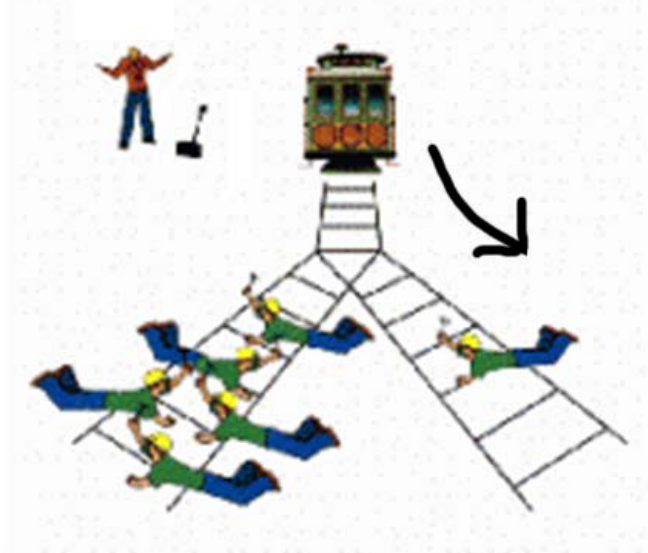
The subjects were given **moral dilemmas** designed to pit **two competing considerations** against one another.



For example, this type of dilemma presents subjects with the **choice of whether or not to sacrifice one person's life to save the lives of others.**

**utilitarian** calculation of how to maximize aggregate welfare **versus**  
a strong **emotional aversion** to the proposed action.

## Impersonal moral scenario


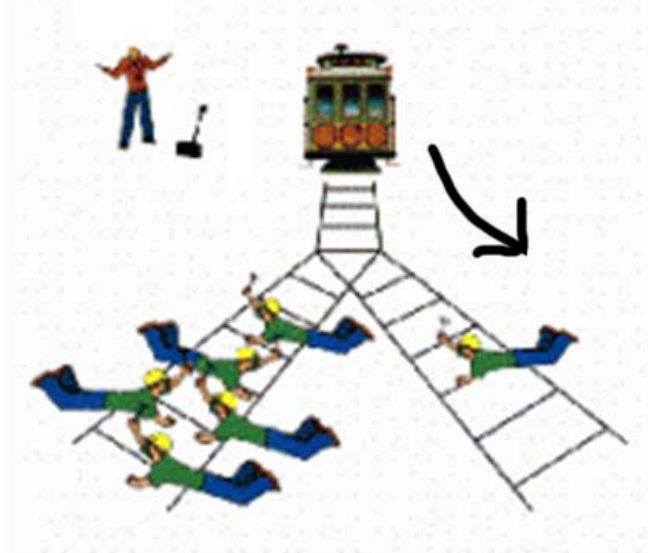


## Personal moral scenario

Flip a switch v. push someone off the bridge to stop the train.



## Impersonal moral scenario



## Personal moral scenario

Flip a switch v. push someone off the bridge to stop the train.

# neurobiological processes underlying moral judgment

Do emotions play a causal role in moral judgment?

Do emotion-related areas of the brain contribute to moral judgment?



Do emotional processes, conscious or unconscious, may also play an important role in moral judgments?

Studies of clinical populations reveal an association between impaired emotional processing and disturbances in moral behavior.

Neuro-imaging studies have consistently shown that tasks involving moral judgment activate brain areas known to process emotions.

Behavioral studies have demonstrated that manipulation of affective states can alter moral judgments.

